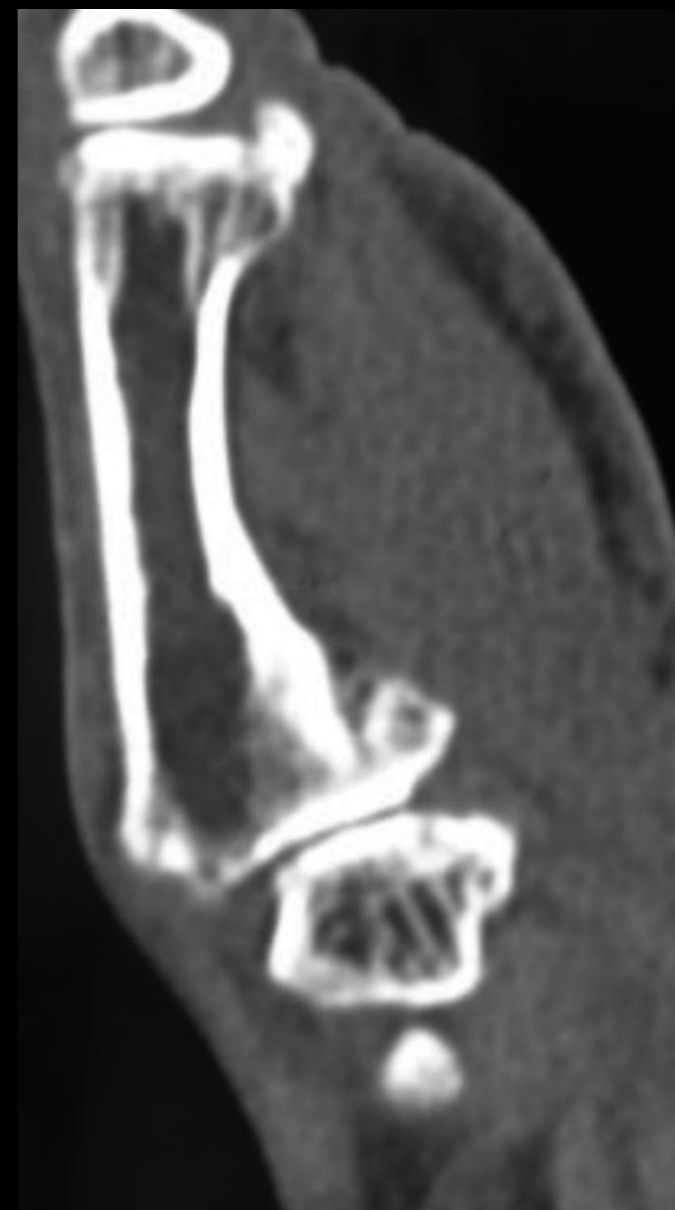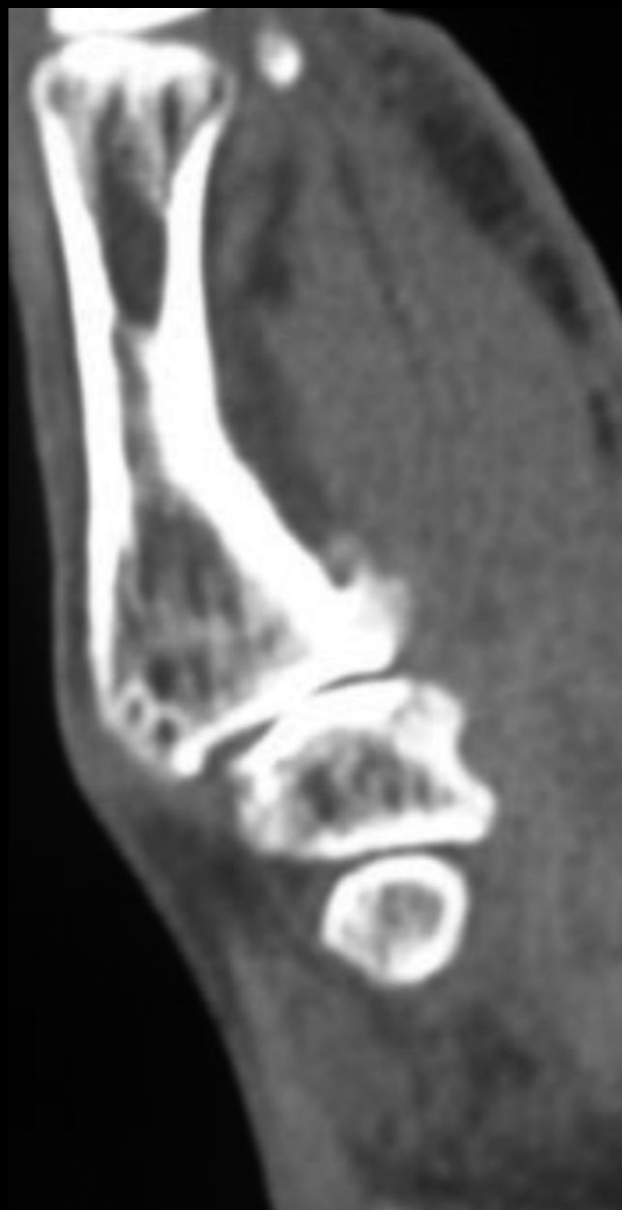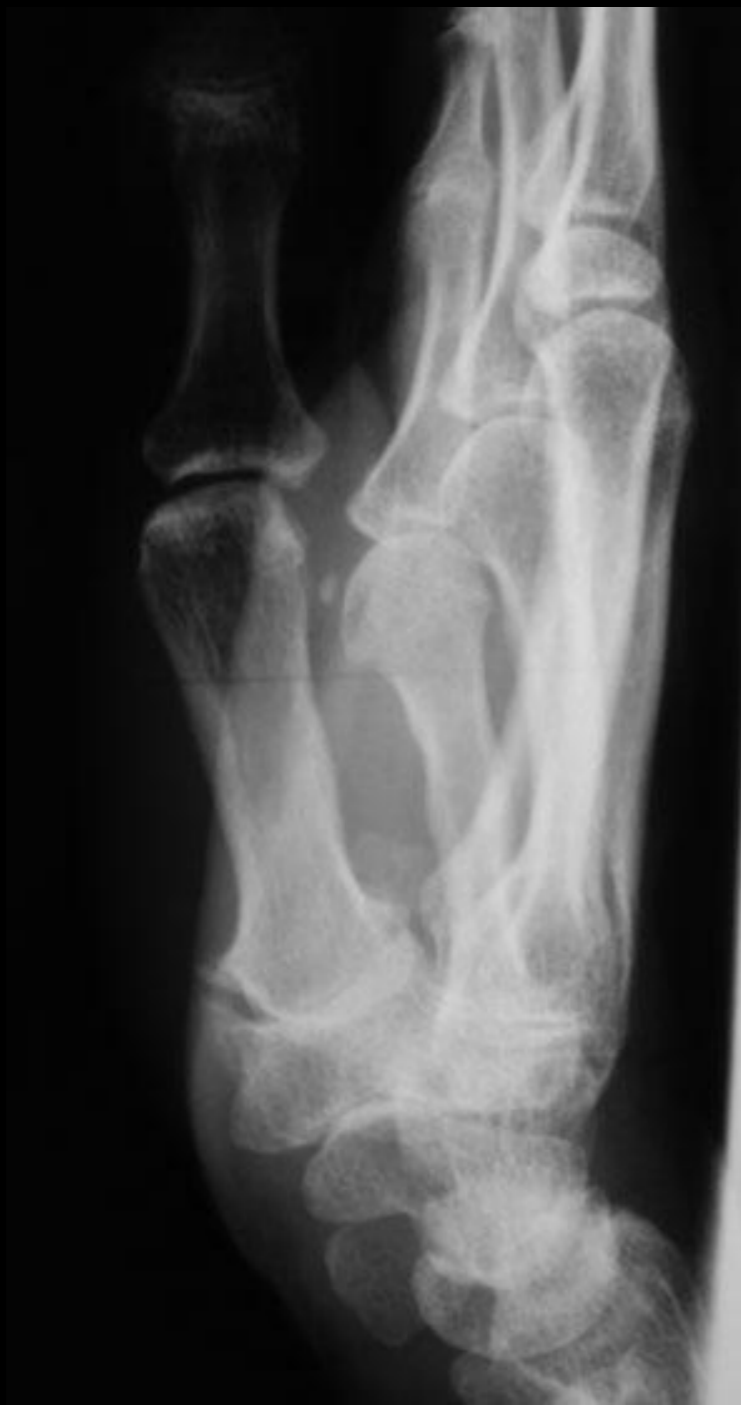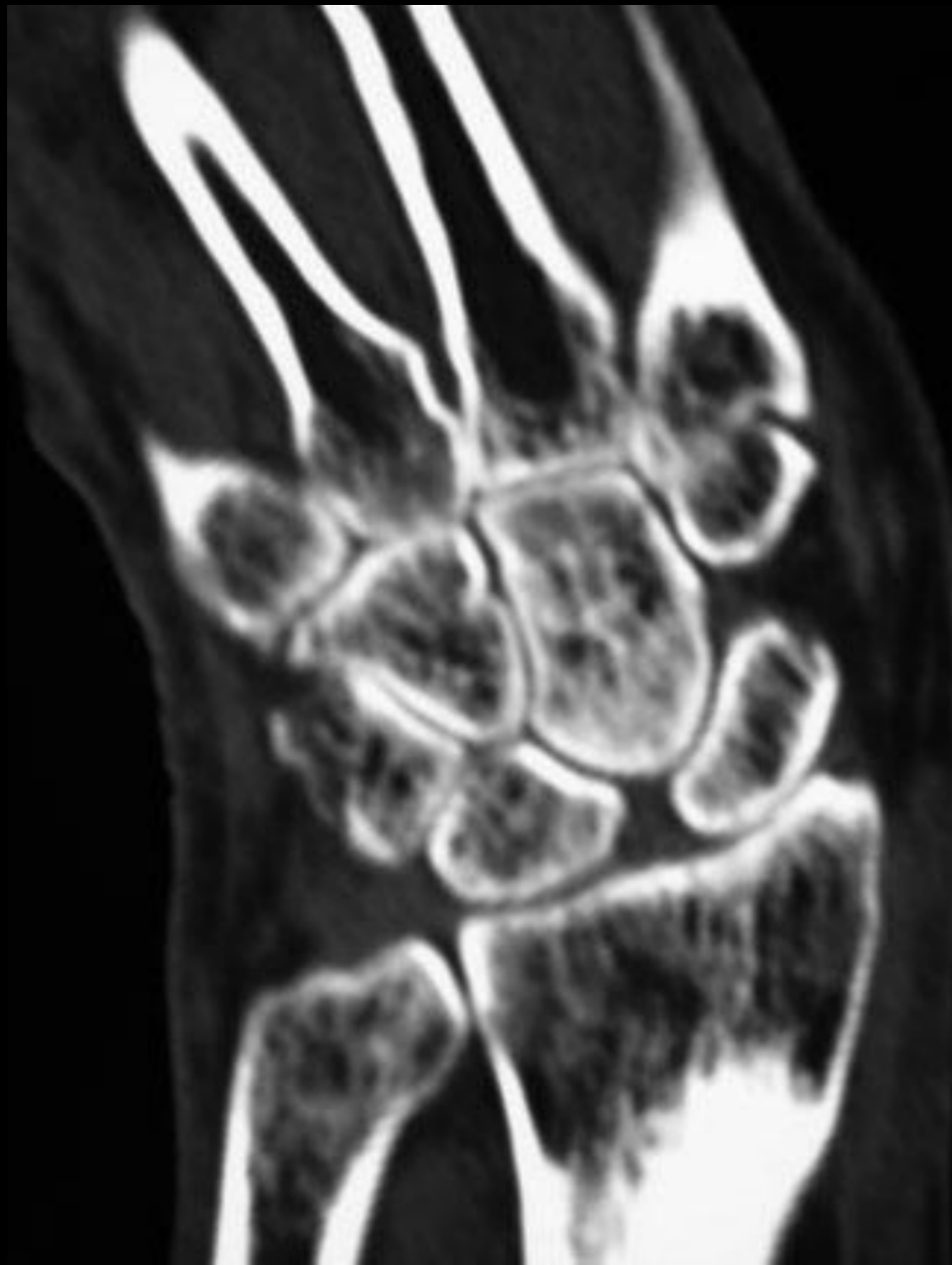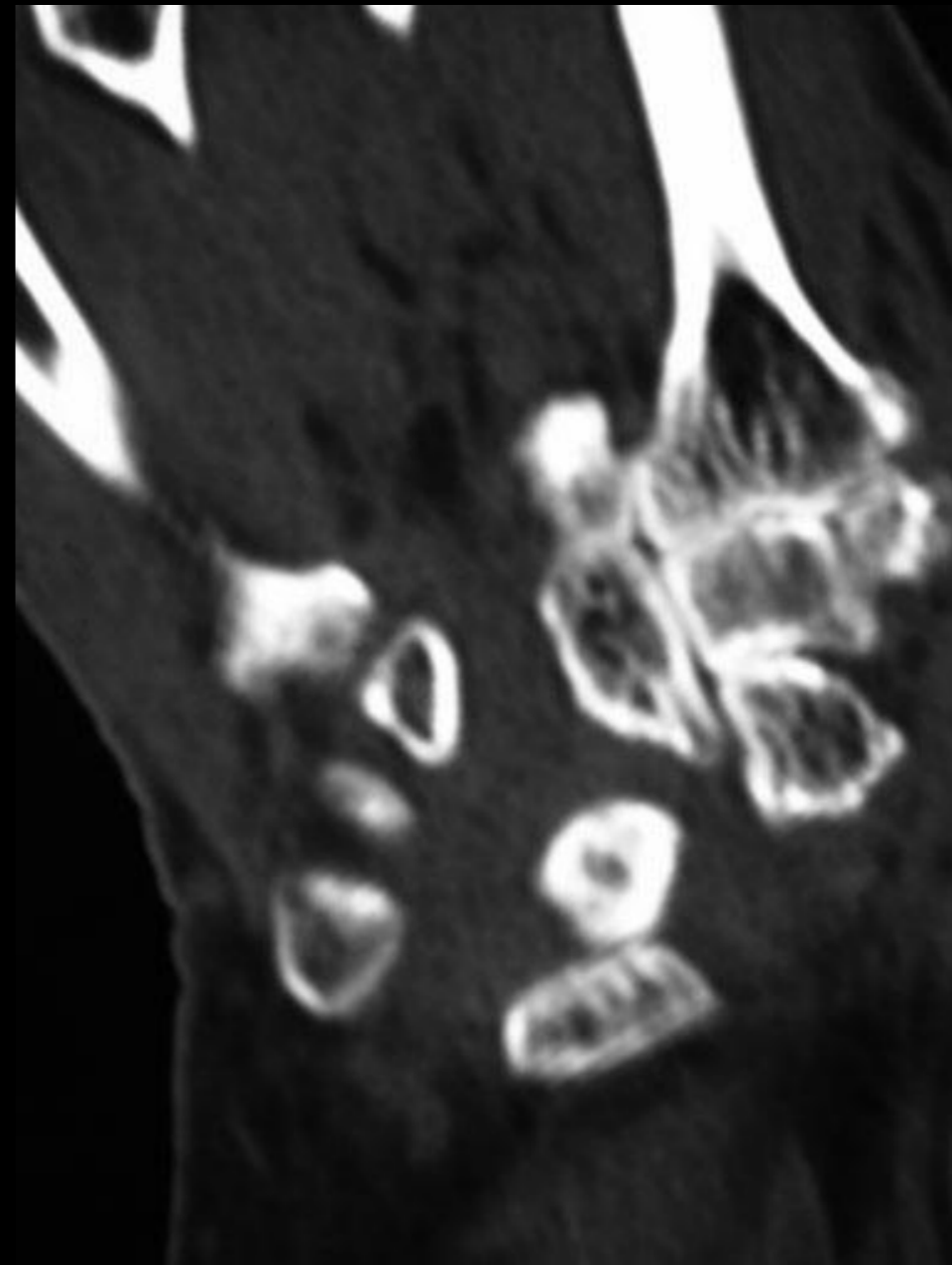


52 y., woman, right





S-L ?

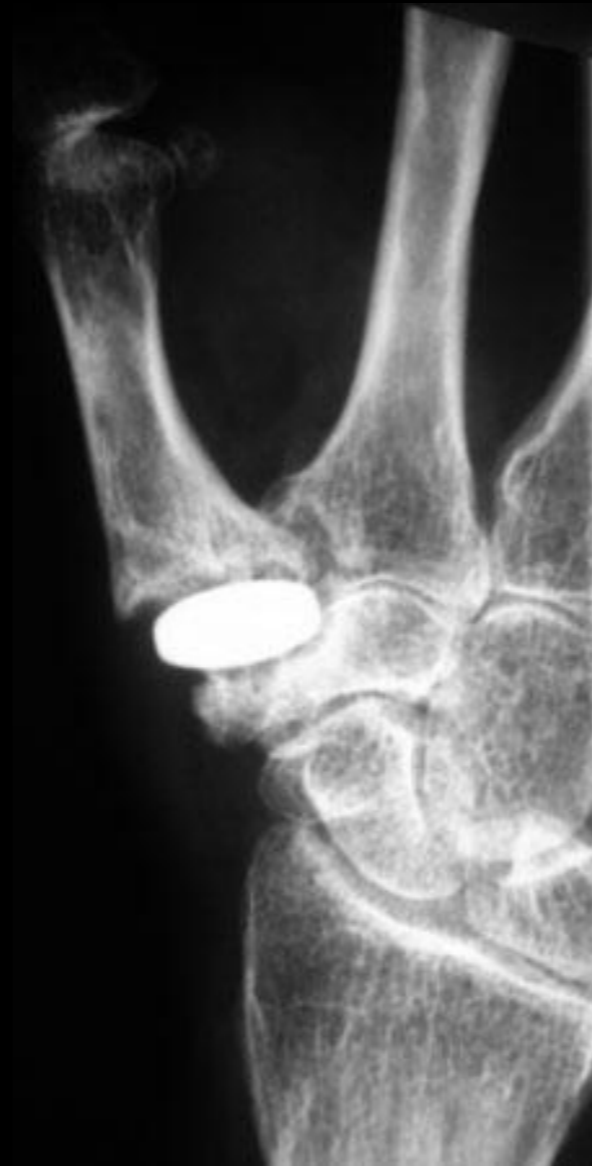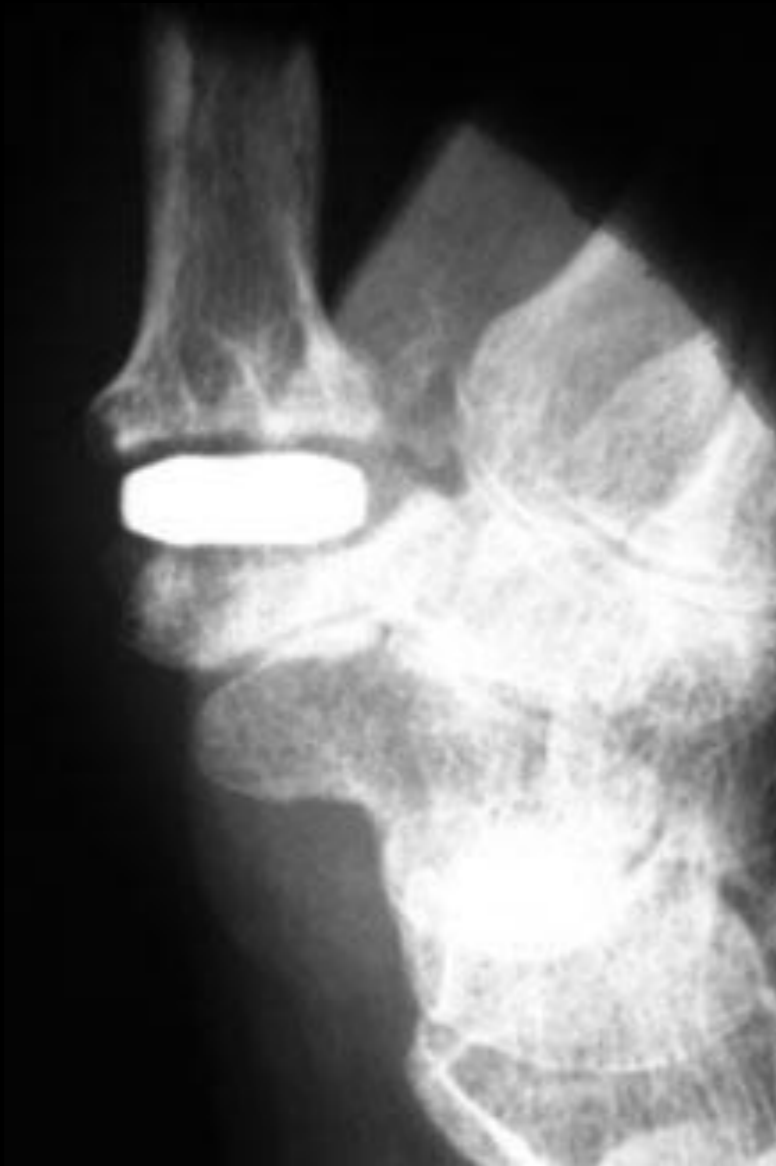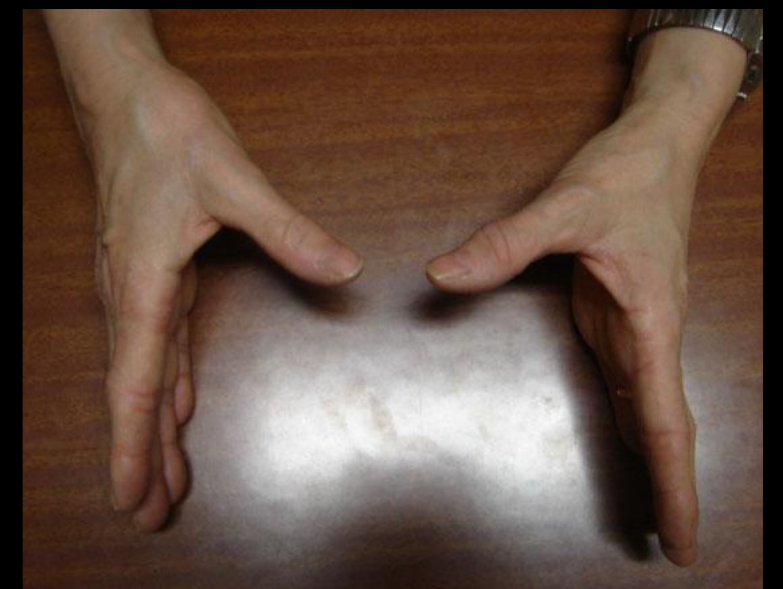


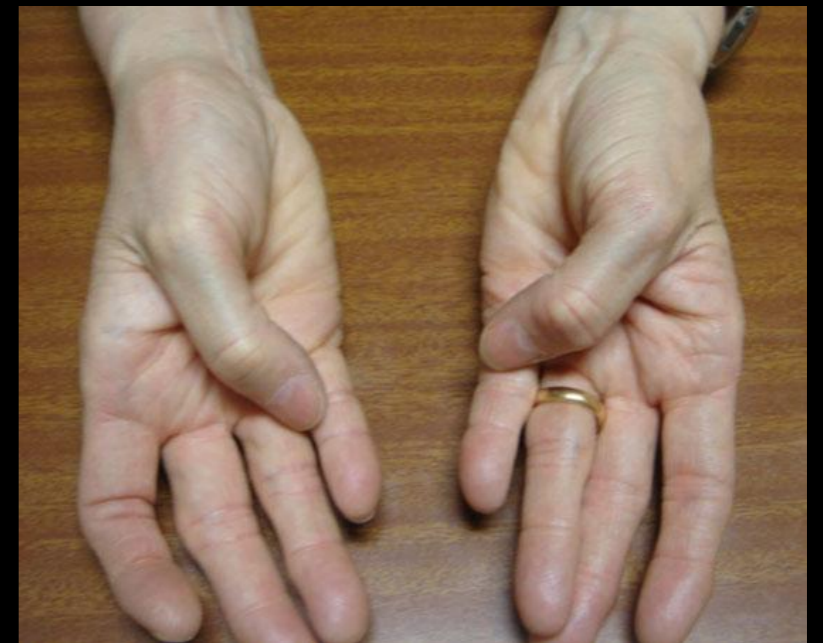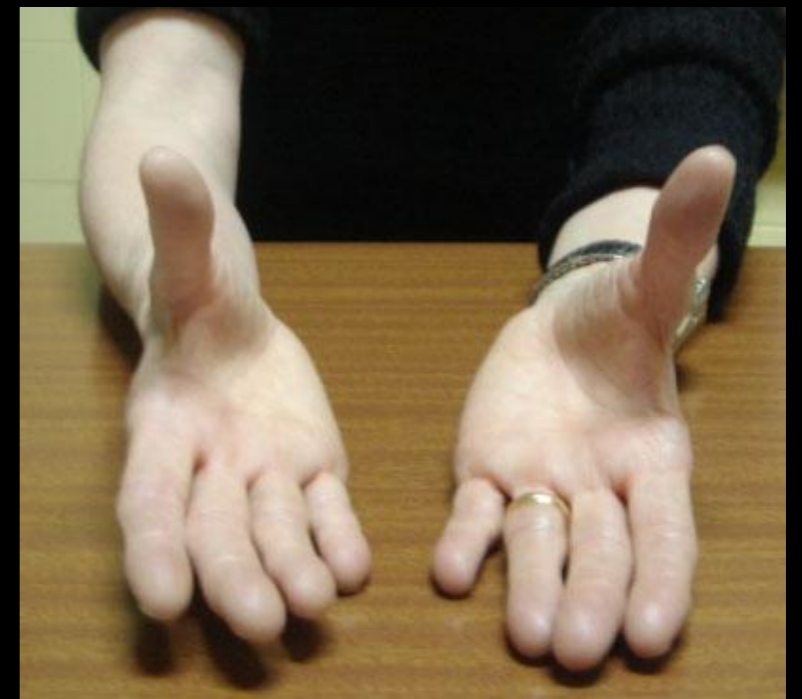Scapho-Trapezoid ?

9 MONTHS

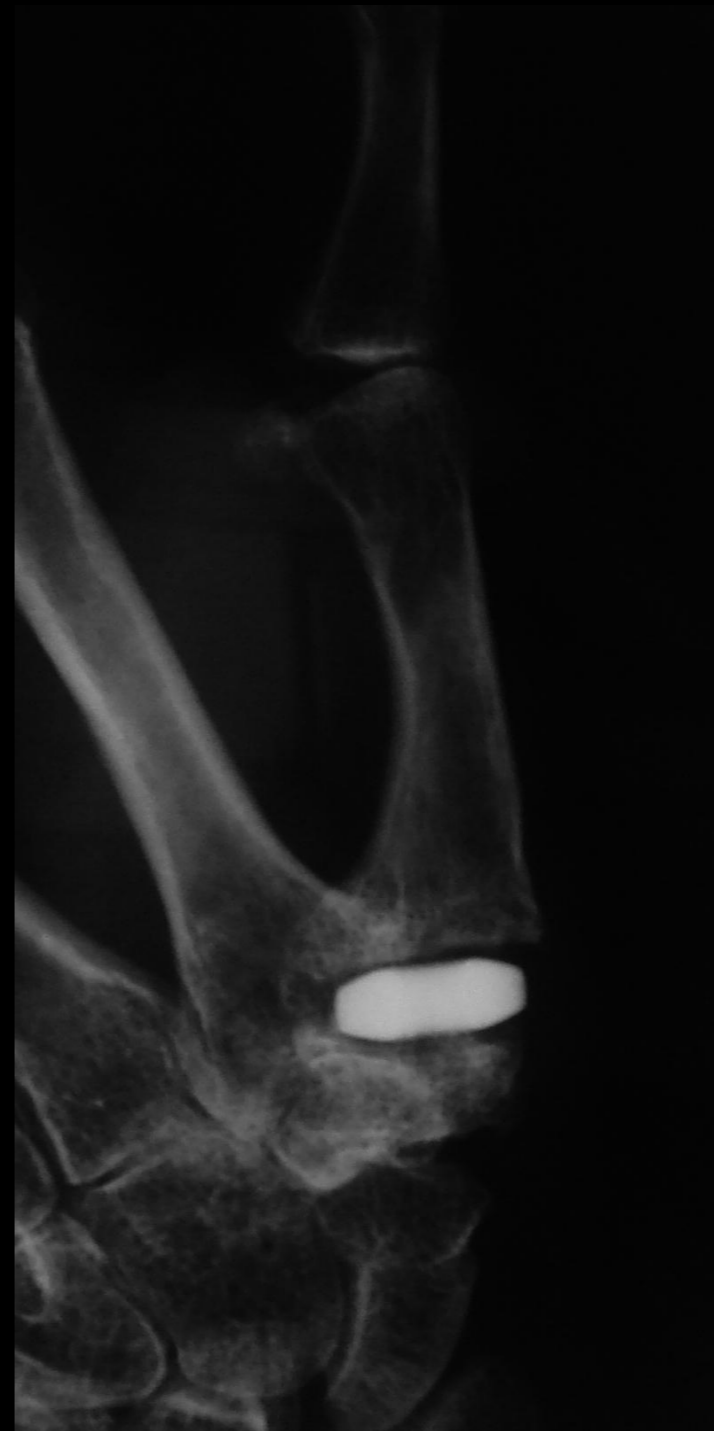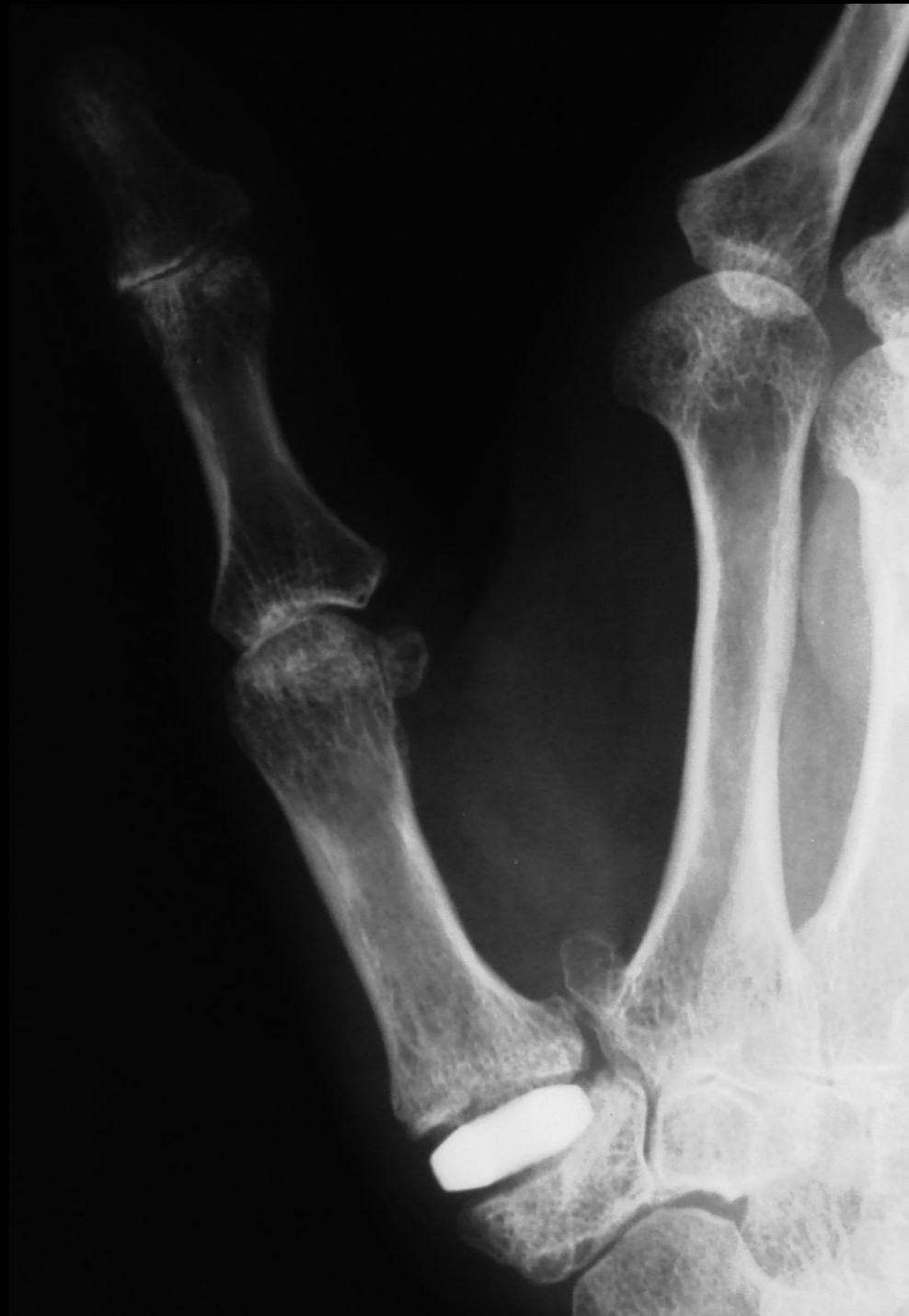VAS: 1

SATISFIED !



3 YEARS  
VERY SATISFIED !

NO PAIN !



Pyrodisc scheduled at the left hand !